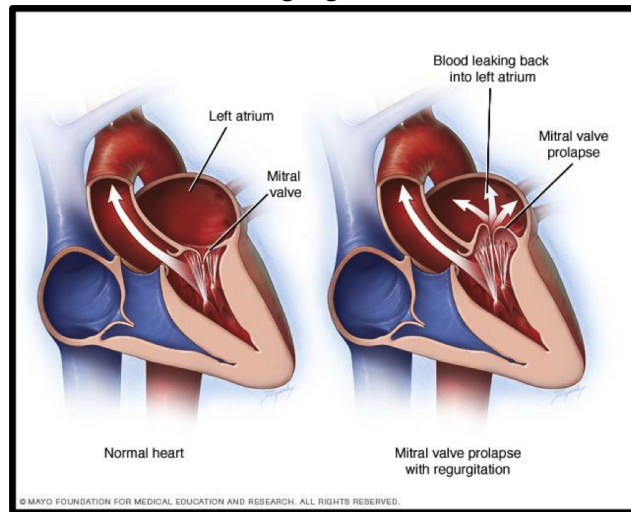


Mitral Regurgitation (MR)



Mitral Regurgitation

Mitral regurgitation (MR) is also commonly known as, myxomatous mitral valve degeneration (MMVD), degenerative mitral valve disease, and endocardiosis (very old terminology). This disease is caused by a degenerative process that occurs in most dogs as they age. In your dog, this process has caused the valve to leak.

In order to understand how this disease may affect your dog, it is important to understand normal circulation in the heart. Blood drains from the body into the right collecting chamber (called "atrium") where it passes through the tricuspid valve and into the right pumping chamber (called "ventricle"). From here, blood is pumped into the pulmonary artery and subsequently to the lungs where it picks up oxygen. The oxygenated blood then drains passively into the left atrium, through the mitral valve, and into the left ventricle. The left ventricle then pumps the blood through the aorta and back to the body.

The mitral valve functions like a saloon door and opens and closes to prevent backflow of blood from the left ventricle to the left atrium. In a normal heart, when the left ventricle pumps, the mitral valve snaps shut, to prevent backflow. In dogs with MR, the valve becomes thickened and starts to leak. The leak in the valve can progressively worsen so that the left ventricle is pumping a significant amount of blood backwards through the leaky valve. Since it also has to pump a normal amount of blood forwards, the left ventricle slowly enlarges. Also, the left atrium enlarges to accommodate the backflow through the mitral valve, and increased pressure in the left ventricle.

Left atrial enlargement is indicative of abnormally high pressure in the left atrium. As the pressure in this chamber increases, it is transmitted back along the blood vessels in the lungs and, if the pressure is high enough, fluid can exude into the alveoli (air sacs) in the lungs. This is called pulmonary edema or congestive heart failure. In many dogs this causes a cough. However, some dogs don't cough when this occurs. Instead, they breathe faster (more than 40 breaths per minute) or with too much effort.

Diagnosing Mitral Regurgitation

Echocardiogram: Dogs with MR will have a heart murmur on the left side of their chest. Your regular veterinarian and cardiologist can grade the intensity of the murmur on a scale of 1-6. Based on the severity of the murmur, and clinical signs, a chest x-ray may be recommended to assess for heart enlargement. However, the best way to evaluate the heart structure and function is by performing a heart ultrasound (called "echocardiogram").

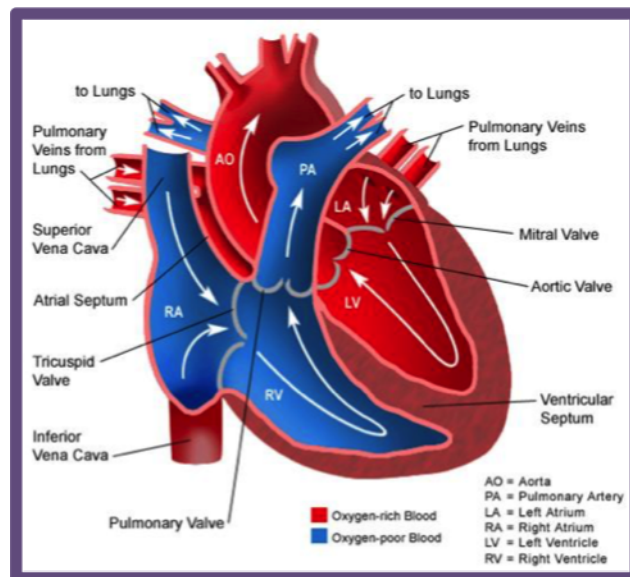
Bloodwork: Depending on the stage of disease, medications may be prescribed. Some cardiac medications can adversely affect the kidneys. For this reason, it is important to monitor kidney function with blood tests as new medications are introduced or dosage changes are made.

Chest X-rays: Chest x-rays are often taken to evaluate for the presence of pulmonary edema. If your dog develops signs of heart failure, this test will likely be recommended.

Electrocardiogram (ECG) and Holter monitoring: Some dogs develop rhythm disturbances secondary to their enlarged hearts. In these cases, an electrocardiogram (ECG) is done. In some cases, a 24 hour ECG monitor (called "Holter monitor") may be recommended to assess response to therapy.

Monitoring Dogs with Mitral Regurgitation

Dogs with MR should be monitored at home for a cough or an increase in respiratory rate (greater than 40 breaths per minute) or effort. If any of these occur, a chest x-ray should be taken to evaluate for the presence of pulmonary edema. Thankfully, most dogs with MR feel good as long as their congestive heart failure is controlled. We will work closely with you and your family veterinarian to ensure that your dog gets the best care possible.



Flow of blood through a normal heart.